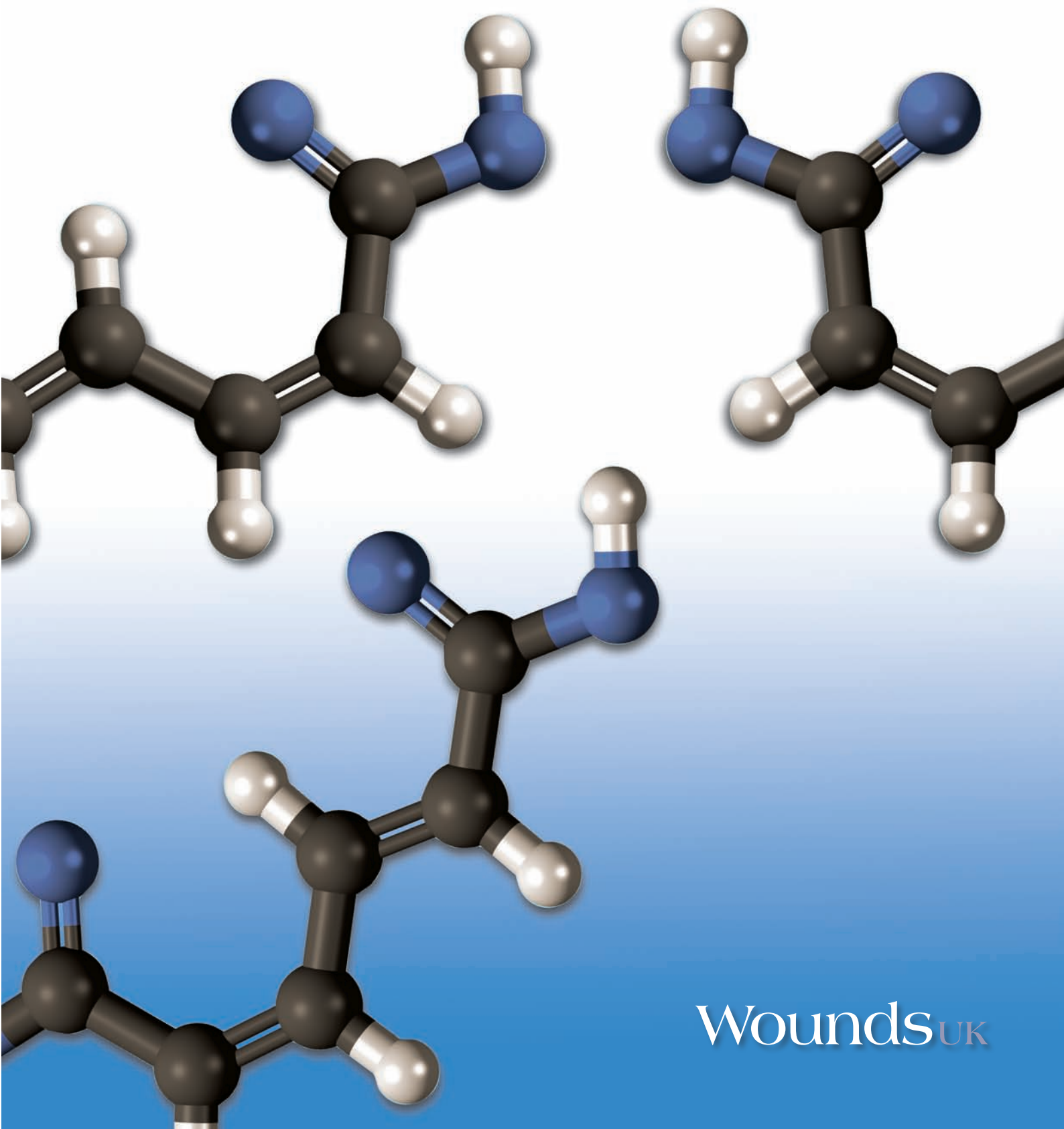


Use of a cellulose PHMB dressing in clinical practice



PUBLISHED BY:

Wounds UK
Enterprise House
1-2 Hatfields
London SE1 9PG, UK
Tel: + 44 (0)20 7627 1510
www.wounds-uk.com

Wounds UK

© **Wounds UK 2014**

This document has been developed by Wounds UK and sponsored by **Medicareplus International**



The views expressed are those of the authors and do not necessarily reflect those of Medicareplus International.

How to cite this document:

Eberlein T, Kanis J. *Use of a cellulose PHMB dressing in clinical practice*. London: Wounds UK, 2014; 10(3). Suppl. Available to download from:
www.wounds-uk.com

Understanding the role of PHMB in removing the barriers to wound healing

Authors:

Thomas Eberlein,
MD, Dermatologist,
Allergologist, Arabian
Gulf University,
Manama, Kingdom of
Bahrain in association
with Wounds UK
Jens Kanis, Senior
Tissue Viability Nurse,
Kreuztal, Germany

Infection is the single most important contributory factor in delayed wound healing. All wounds contain micro-organisms (mainly bacteria), but not all wounds will become infected. The potential for bacteria to delay healing is influenced by the ability of the patient's immune system to combat the bacteria as well as the number and type of bacteria present (WUWHS, 2008). Prevention of wound infection should be a primary management objective for all clinicians, while early diagnosis can reduce the risk of complications and treatment costs (White, 2009).

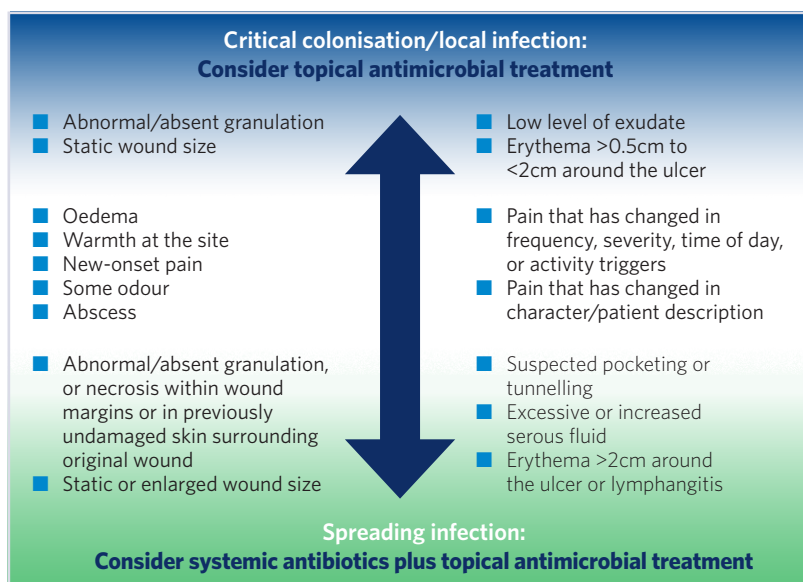
Diagnosing infection is primarily a clinical skill. However, not all wounds present with the classical signs of redness, heat and swelling and sometimes more subtle signs may indicate localised infection or persistent inflammation (e.g. caused by biofilm) (Phillips et al, 2011).

Effectively managing and treating wound infection can also be challenging, clinicians having a wide range of products and pharmaceutical interventions to choose from. However, indiscriminate use of antibiotics has led to the rising prevalence of resistant organisms, with the potential to jeopardise patient outcomes (EWMA, 2013). This has led to the need to restrict their use to essential indications and a focus on local wound management using topical antimicrobials as a first-line treatment to manage wound bioburden, particularly in chronic wounds.

Topical antimicrobials should be used only when signs and symptoms suggest wound bioburden is interfering with healing (Figure 1). The decision about which topical antimicrobial to select should be made on the basis of knowledge, experience and evidence (Kramer et al, 2010).

FIGURE 1:

Signs and symptoms of infection with options for treatment (reproduced from Topical Antimicrobial Quick Guide, Wounds UK. Available from: www.wounds-uk.com)



WHAT IS PHMB?

Polyhexamethylene biguanide (PHMB) is a broad-spectrum antimicrobial substance that has been used for 60 years in a wide range of medical and non-medical applications (Davies et al, 1954; Eberlein and Assadian, 2010). It has been used safely in wound care since the early 1990s; it is well tolerated and has a low-risk profile (Kaehn, 2010).

PHMB works by attaching to the surface molecules of the microbial cell and disrupting its membrane and metabolism. This causes a loss of cell function and, ultimately, destruction of the microbial cell (Kaehn, 2010).

TABLE 1: SUMMARY OF CLINICAL EVIDENCE FOR PHMB				
Author	Title of Paper	Type of Study	Purpose	Outcome
Schmidt-Neuerberg et al. <i>Chirurg.</i> 2001 Jan;72(1):61-71	[Effectiveness of an improved antiseptic in treatment of contaminated soft tissue wounds] German	RCT, double-blind (n=80)	To compare the effect of gauze compresses soaked in 0.2% PHMB (n=45) and Ringer 's lactate solution (n=35)	PHMB group had better wound healing and faster reduction of Gram-positive infections. Better tissue compatibility was also observed with PHMB compared to the control group
Roth et al. <i>GMS Krankenhaushyg Interdiszip</i> 2007;2: Doc58(20071228)	[Surgical site infections after primary antiseptic cleansing of dirty-contaminated wounds by polyhexanide, PVP-iodine resp hydrogen peroxide] German	Retrospective, open-label, multicentre RCT (n=7,862)	To compare rate of postoperative infections with PHMB, povidone iodine, Ringer's solution and hydrogen peroxide	Lowest frequency of postoperative wound infection was observed in wounds treated with PHMB after wound debridement
Daeschlein et al. <i>Skin Pharmacol Physiol</i> 2007;20(6):292-6	Feasibility and clinical applicability of polyhexanide for treatment of second-degree burn wounds	Feasibility study (n=18)	To compare the efficacy of PHMB, silver nitrate and povidone iodine in the treatment of second-degree burns (n=14) and poorly healing pressure ulcers with mesh grafts (n=4)	PHMB was superior to povidone-iodine and silver nitrate in terms of regeneration of the epithelium, with reduction in wound pain and improved patient comfort. There was a reduction in fibrin formation compared to silver nitrate treatment
Andriessen and Eberlein. <i>Wounds</i> 2008; 20:71-75	Assessment of wound cleansing solution in the treatment of problem wounds	Retrospective review (n=59)	To compare the clinical efficacy of PHMB solution with Ringer's solution or saline (control) in venous ulcers	Significant difference between treatment groups (P<0.0001) in time to healing. PHMB-treated wounds healed faster and in more cases with a lower risk of secondary infection
Mueller and Krebsbach, 2008. <i>Am J Infect Control</i> 36(9):651-5	Impact of an antimicrobial-impregnated gauze dressing on surgical site infections including methicillin-resistant <i>Staphylococcus aureus</i> infections	Observational (n=10,202 procedures)	To observe the rate of SSIs following an institutional change from the application of a sterile plain dressing to the application of PHMB-impregnated dressings on postoperative wounds	Following the switch to PHMB-impregnated dressings, 84 SSIs occurred after 10,202 surgical procedures (0.82%), representing 24.07% (P =0.035) rate reduction in SSIs. 11 identified as MRSA (0.11%), representing a rate reduction of 47.62%. May reduce post-surgical costs
Valenzuela et al. <i>Rev Enferm</i> 2008; 31:7-12	[The effectiveness of a 0.1% polyhexanide gel]	Randomised, non-blinded, multicentre (n=142)	To compare efficacy of 0.1% PHMB gel with standard of care to control bacterial burden in chronic wounds	After 2 weeks, PHMB reduced bacterial bioburden, decreased wound area, slough in wound bed, pain and exudate and increased granulation tissue compared with standard care treatments
Galitz et al. Poster presentation, EWMA 2009	Polyhexanide versus silver wound dressings - first interim results of a controlled, randomised, prospective, multicentre study	Prospective, multicentre RCT (n=21)	To compare a PHMB-containing biocellulose dressing with best local silver standard of wound care in critically colonised or locally infected wounds	Both dressing regimens achieved a positive antimicrobial effect. The PHMB product was significantly more effective in reducing the pain after the dressing change compared to silver
Roth and Kramer. <i>GMS Krankenhaushyg Interdiszip</i> 2009; 4:Doc16(20091216)	Supportive antiseptic therapy of ulcer cruris with polyhexanide	Observational, follow-up (n=259)	To report on the efficacy of polyhexanide (0.04%) soaked dressings following surgery in patients with chronic venous ulcers	After 3 days of antiseptic therapy, 72 ulcers (30.7%) were bacteriologically negative; after 7 days, 139 (60.1%). At the time of follow-up, 203 patients (87.8%) were free of recurrence
Romanelli et al. <i>Skin Pharmacol Physiol</i> 2010; 23(suppl):41-44	Evaluation of the efficacy and tolerability of a solution containing propyl betaine and polyhexanide for wound irrigation	Single-blind, single-centre, prospective, controlled comparison trial (n=40)	To evaluate the efficacy and tolerability of a wound cleansing solution containing PHMB to control bacterial burden in chronic wounds	Group receiving PHMB-containing wound cleansing solution reported better pain control at the end of treatment (P<0.05) than control group. PHMB was well tolerated, with better control of wound odour and a significantly better control of wound bioburden
Sibbald et al, 2011. <i>Adv Skin Wound Care</i> 2011 Feb;24(2):78-84	Reduction of bacterial burden and pain in chronic wounds using a new polyhexamethylene biguanide antimicrobial foam dressing-clinical trial results	RCT in patients with chronic foot or leg ulcers (n=45) followed for 5 weeks	To evaluate the effectiveness of a PHMB foam dressing compared with a similar non-antimicrobial foam	PHMB foam dressing was a significant predictor of reduced wound size and lower superficial bacterial burden when compared to the non-antimicrobial dressing (P=0.016). There was also a significant reduction in pain at week 2 (P=0.0006) and at week 4 (P=0.02)

Studies have shown that PHMB is effective against a broad spectrum of micro-organisms, including both Gram-positive and Gram-negative bacteria (Gilbert and Moore, 2005), and selected fungi (Yanai et al, 2011) as well as resistant organisms such as methicillin-resistant *Staphylococcus aureus* (MRSA) (Kirker et al, 2009). PHMB has also been shown *in-vitro* to be effective against bacteria in biofilms (Kaehn, 2010; Hüber et al, 2010). Because of its multi-modal action, acquired resistance to PHMB is unlikely (Gilbert and McBain, 2001).

PHMB is increasingly used in wound care because of its good biocompatibility. It is available, for example, as a cleansing solution (Prontosan®, B Braun) and as impregnated dressings such as CelluDress-PHMB (Medicareplus International — also known as VULCOSAN®, Hawest Research AG). In concentrations up to 0.3%, PHMB has been described as ‘practically non-toxic’ (Hüber and Kramer, 2010), with good cell and tissue tolerability and a very low risk of sensitisation (Eberlein and Assadian, 2010).

CLINICAL EVIDENCE FOR PHMB

The use of PHMB is well-established in wound care. It has been demonstrated to have positive effects on wound healing and may reduce wound pain, odour and slough, providing an alternative antimicrobial agent to silver, honey or iodine (Butcher, 2012; Vowden et al, 2011). Some of the key clinical papers are highlighted in Table 1.

The results of *in-vivo* and *in-vitro* studies of PHMB led Dissemmond et al (2010) to recommend that PHMB be used as the primary topical antimicrobial for the treatment of critically colonised or locally infected acute and chronic wounds.

RATIONALE FOR TREATMENT

The primary objective is to eliminate the clinical signs of infection (e.g. reduce pain, exudate and odour and encourage granulation tissue formation) or to reduce the risk of infection developing (Dissemmond et al, 2011). In general, the duration of topical antimicrobial treatment is 7-14 days at which time there should be a review of the wound and antimicrobial treatment stopped if the therapy is successful (Wounds UK BPS, 2013). The continuation of antimicrobial treatment is only justified on the basis of a full risk/benefit assessment (i.e. its ability to kill bacteria versus risk of damaging the wound bed). For preparations containing PHMB, which has been shown to have low cytotoxicity (Roth et al, 2010), consideration may be given to longer periods of use, providing regular review is performed to ensure the ongoing suitability of the product (Eberlein and Assadian, 2010).

CELLUDRESS-PHMB

CelluDress-PHMB is a sterile moist wound dressing impregnated with a special PHMB Antimicrobial Complex. The dressing has a three-layer structure. The two outer layers are non-adherent to minimise adherence to the wound and improve patient comfort. The middle biocellulose layer is designed to function as a reservoir for the antimicrobial solution as well as an absorption layer for wound pathogens. The dressing protects against the development of wound infection by absorbing and binding to the negatively-charged micro-organisms, decreasing the bacterial load in the dressing and preventing bacterial growth in the wound (Edwards-Jones et al, 2013).

INDICATIONS FOR USE

CelluDress-PHMB is indicated for acute and chronic wounds at risk of infection, with low to moderate exudate. It can be used at different stages of healing to promote granulation, while providing antimicrobial protection and effective exudate management. It can also be used under compression. Examples of wound types that can be considered for treatment include:

- First and second degree burns
- Post-surgical wounds

- Traumatic wounds
- Chronic leg ulcers (venous, arterial or mixed)
- Diabetic foot ulcers
- Pressure ulcers.

CelluDress-PHMB should only be used on skin wounds or mucosal membranes and should not be used where bone tissue is exposed, where there is cartilage damage or there is known hypersensitivity to one of the ingredients. It may be used on babies or pregnant women in consultation with the lead clinician only.

TOP TIPS FOR PRACTITIONERS

- The dressing can be cut and shaped to fit the wound.
- For deeper wounds, the dressing can be cut into strips and shaped to fit the wound.
- The dressing should not be allowed to dry out. For low exuding wounds, apply an appropriate secondary dressing to minimise the risk of wound dehydration.
- For wounds with moderate to high levels of exudate, use a non-adherent absorbent secondary dressing.
- Affix the dressing with adhesive tape or retention bandage.
- Daily changing is recommended for infected wounds. For all other wounds, dressings should not be left on the wound for longer than 3 days.
- The safety and excellent tissue compatibility of PHMB allows application over a long period of time. Review suitability at each dressing change.
- When there is suspicion of deep or spreading infection, start treatment with systemic antibiotics.

USING CELLUDRESS-PHMB IN PRACTICE

In 2013, Hagelstein and Ivins reported on the use of CelluDress-PHMB in 5 patients with recalcitrant wounds at high risk of infection or reinfection. The nurses rated the dressing performance as good, it was easy to apply and remove, and did not cause discomfort on removal or during wear (Hagelstein and Ivins, 2013). Using the dressing led to a clear improvement in patient comfort and quality of life. The following case reports collected from the caseload of a tissue viability nurse working in Germany, look at the use CelluDress-PHMB in patients with various wound aetiologies.

REFERENCES

- Butcher M (2012) PHMB: an effective antimicrobial in wound bioburden management. *Br J Nursing* 21(12): 516-21
- Davies GE, Francis J, Martin AR et al (1954) 1:6-DI-4D Chlorophenyldiguanidohehexane ('Hibitane'). Laboratory investigation of a new antibacterial agent of high potency. *Br J Pharmacol Chemother* 9(2): 192-96
- Dissemond J, Gerber V, Kramer A, et al (2010) A practice-orientated expert recommendation for treatment of critically colonised and locally infected wounds using polihexanide. *J Tissue Viability* 19(3): 106-15
- Dissemond J, Assadian O, Gerber V et al (2011) Classification of wounds at risk and their antimicrobial treatment with polyhexanide: a practice-orientated expert recommendation. *Skin Pharmacol Physiol* 24(5): 245-55
- Eberlein T, Assadian O (2010) Clinical use of polihexanide on acute and chronic wounds for antiseptics and decontamination. *Skin Pharmacol Physiol* 23(suppl 1): 45-51
- Edwards-Jones V, Ivins N, Ladwein S (2013) CelluDress-PHMB Made Easy. *Wounds UK* 9(3): Suppl
- EWMA Document (2013) Antimicrobials and non-healing wounds: Evidence, controversies and suggestions. MA Healthcare, London. Available at: <http://bit.ly/1k7CvCg>
- Gilbert P, McBain AJ (2001) Biofilms: their impact on health and their recalcitrance toward biocides. *Am J Infect Control* 29(4): 252-55
- Gilbert P, Moore LE (2005) Cationic antiseptics: diversity of action under a common epithet. *J Appl Microbiol* 99(4): 703-15
- Hagelstein S, Ivins N (2013) Treating recalcitrant venous leg ulcers using a PHMB impregnated dressing: A case study evaluation. *Wounds UK* 9(4): 84-90
- Hüber NO, Kramer A (2010) Review on the efficacy, safety and clinical applications of polyhexanide, a modern wound antiseptic. *Skin Pharmacol Physiol* 23 (suppl 1): 17-27
- Hüber NO, Matthes R, Koban I, et al (2010) Efficacy of chlorhexidine, polihexanide and tissue-tolerable plasma against *Pseudomonas aeruginosa* biofilms grown on polystyrene and silicone materials. *Skin Pharmacol Physiol* 23 (suppl 1): 28-34
- Kaehn K (2010) Polihexanide: a safe and highly effective biocide. *Skin Pharmacol Physiol* 23(suppl 1): 7-16
- Kirker KR, Fisher ST, James GA, et al (2009) Efficacy of polyhexamethylene biguanide-containing antimicrobial foam dressing against MRSA relative to standard foam dressing. *Wounds* 21(9): 229-33
- Kramer A, Hüber NO, Assadian O, Mulder G (2010) Polihexanide - perspectives on clinical wound antiseptics. *Skin Pharmacol Physiol* 23(suppl 1): 1-3
- Phillips PL, Wolcott R, Fletcher J, Schultz G (2010) Biofilms Made Easy. *Wounds International* 1(3) Suppl. Available from www.woundsinternational.com
- Roth C, Buele AG, Kramer A, et al (2010) Response analysis of stimulating efficacy of polihexanide in an in vitro wound model with respiratory ciliary epithelial cells. *Skin Pharmacol Physiol* 23(Suppl 1): 35-40
- Vowden P, Vowden K, Carville K (2011) Antimicrobial dressings Made Easy. *Wounds International* 2(1). Suppl. Available at www.woundsinternational.com
- White RJ (2009) Wound infection-associated pain. *J Wound Care* 18(6): 245-49
- World Union of Wound Healing Societies (WUWHS) (2008) *Wound infection in clinical practice. An international consensus*. MEP Ltd, London. Available from: www.woundsinternational.com
- Wounds UK (2010) *PHMB and its potential contribution to wound management. A consensus document*. Wounds UK, London. Available at: www.wounds-uk.com
- Wounds UK Best Practice Statement (2013) *The use of topical antiseptic/antimicrobial agents in wound management*. Wounds UK, London. Available from: www.wounds-uk.com
- Yanai R, Ueda K, Nishida T et al (2011) Effects of ionic and surfactant agents on the antimicrobial activity of polyhexamethylene biguanide. *Eye Contact Lens* 37(2): 85-9

CASE STUDIES

CASE 1: PRESSURE ULCER TO RIGHT BUTTOCK

This 96-year-old woman presented to the tissue viability team on 7 November 2013. She had developed Category III pressure ulcers on her back and right buttock from sitting too long in her chair. She was able to live at home, assisted by 24-hour social care. The patient was encouraged to mobilise, but found it difficult to cooperate, which resulted in long periods spent sitting in her chair.

Both ulcers were malodorous and exudate levels were moderate. The pressure ulcer on the right buttock contained yellow-black fibrinous necrotic tissue, and there were signs of local infection, with erythema, heat local to the wound and malodour (Figure 1). Wound-related pain was rated as a 2-3 on a 0-10 scale.

TREATMENT

It was decided to treat both ulcers using the same regimen as follows:

- Wound cleansing with PHMB wound irrigation solution (Prontosan, B Braun) and hydrogel to accelerate autolytic debridement of the fibrinous necrotic coating
- Cellulose with PMHB dressing (CelluDress-PHMB), cut to size to fit the wound area covered with a hydropolymer dressing with adhesive border (Suprasorb P, Lohmann & Rauscher).

The dressings were changed 3 times a week and adequate pressure relief was provided. This case study focuses on the progress of the pressure ulcer on the right buttock.

Over the treatment course, there was rapid loosening of the fibrinous necrotic coating and reduction in wound exudate level from high to none. The malodour resolved after 2 weeks. After 4 weeks, the wound area had decreased (from 9.24cm² to 3.46cm² — an overall reduction of 62.5% from baseline) (Figure 2). The dressing change frequency was left unchanged. However, the periwound skin became inflamed and irritated due to the adhesive border of the secondary dressing. Cortisone cream was applied for a short duration and the secondary dressing was changed to one with a non-adhesive border. There was a slight increase in the wound area to 3.77cm² due to removal of devitalised tissue, with evidence of granulation tissue formation and epithelialisation.

After these changes to the dressing regimen, the ulcer continued to improve over the following 4 weeks with a reduction in wound size (0.67cm²) and no wound-related pain. Evidence of granulation tissue was seen in the wound bed and the ulcer went on to heal successfully (Figure 3).

SUMMARY

CelluDress-PHMB dressing was able to overcome the problems of local infection in this pressure ulcer that went on to heal successfully. The pressure ulcer on the patient's back also healed within a similar timeframe with no complications. The patient was advised to continue her skin care regimen, and pressure ulcer prevention measures, including appropriate pressure relief, to prevent recurrence, were also maintained.

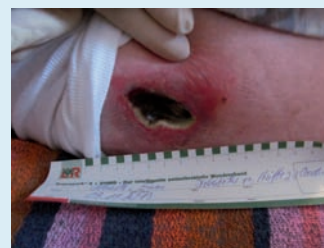

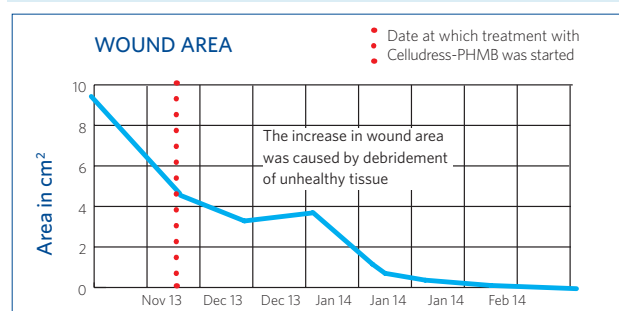
FIGURE 1. Pressure ulcer at start of treatment with CelluDress-PHMB (7.11.2013)

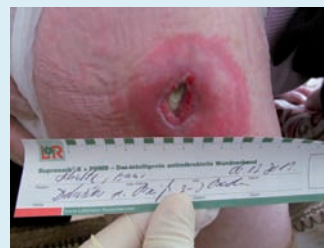

FIGURE 2. Irritation of periwound skin (6.12.2013). The application of a hydrogel had led to a softening of the necrotic tissue

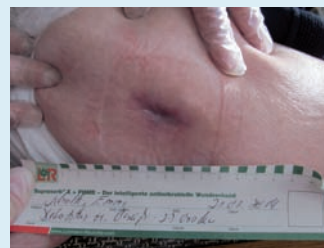

FIGURE 3. Wound healed (21.2.2014)



CASE STUDIES

CASE 2: IMPAIRED WOUND HEALING FOLLOWING SURGERY

An 81-year-old gentleman with lymphatic venous insufficiency was referred by the general practitioner to the tissue viability nurse. He presented with impaired wound healing following surgery to repair fractures of the left upper ankle and calf bone. This had been fixed surgically using a plate and screws 2 years' previously.

The wounds on his left upper ankle region — one medial and one lateral — failed to heal due to the metallic fixations of the bone structures. Treatment with a silver Hydrofiber® dressing and an absorbent secondary dressing under compression was adopted initially, but healing became stalled.

Surgical removal of the fixation screw at the upper ankle, which was exposed at the wound base, was therefore performed on 9 September 2013. Removal of the fixed metal plate in the lateral upper ankle was not possible. Postoperatively, there was swelling and inflammation in the suture region with strong yellow exudate (Figure 1a and b). Due to further deterioration and delayed healing, treatment was switched on 30 October 2013 to a cellulose PHMB dressing (CelluDress-PHMB).

TREATMENT

Both wounds were cleansed using a PHMB wound irrigation solution (Prontosan W, B Braun). A cellulose PHMB dressing, was placed in the wound and 1cm surrounding the edge of the wound, covered by a secondary absorbent dressing. Inelastic compression was applied to both lower limbs. The dressing interval was initially every other day; this was subsequently reduced to three times a week due to reduced exudate.

MEDIAL ASPECT ULCER

The wound initially increased in size over the following 4 weeks (from 1.06cm² to 2.41cm²) due to debridement of devitalised tissue (Figure 2), but showed a dramatic reduction in size over the following three months of treatment (0.70cm²) (Figure 3).

There was an initial increase in exudate, reducing over time and improving in colour (from brownish-yellow, through to yellowish-red). The wound appeared less inflamed and continued to improve 5 months after the start of treatment, with evidence of significant granulation in the wound bed and reduction in wound area (Figure 4).

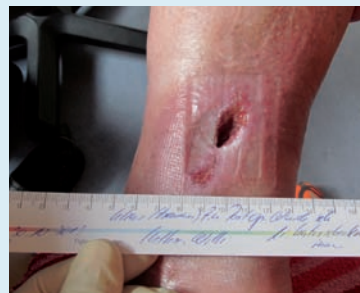

FIGURE 1a. Medial ulcer postoperatively (30.10.2013)

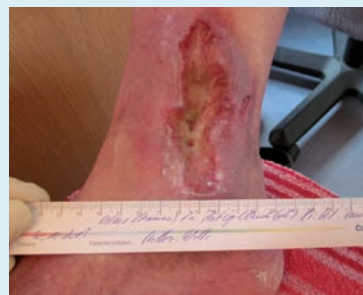

FIGURE 1b. Lateral wound postoperatively (30.10.2013)

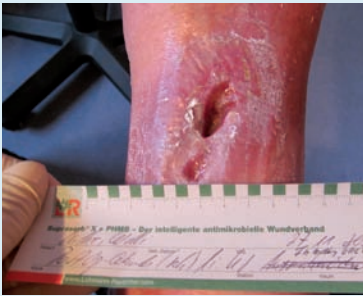

FIGURE 2. Medial ulcer after 4 weeks' treatment with CelluDress-PHMB (27.11.2013)

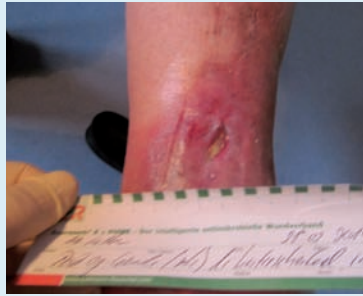

FIGURE 3. Medial ulcer after 3 months' treatment with CelluDress-PHMB (28.02.2014)

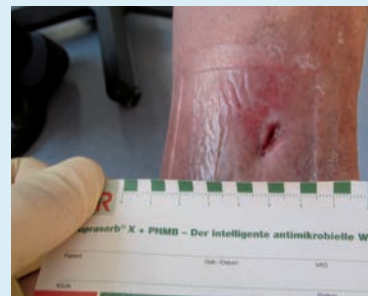

FIGURE 4. Continued improvement after a further 4 weeks (28.03.2014)

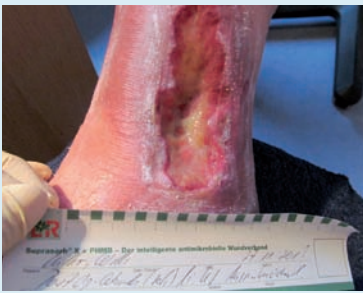

FIGURE 5. Lateral wound after 4 weeks' treatment with CelluDress-PHMB (27.11.2013)

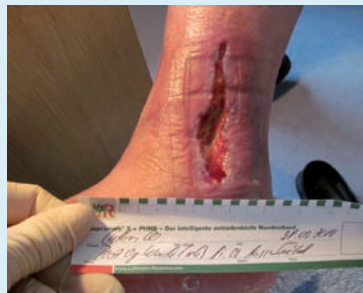

FIGURE 6. Lateral wound after 3 months' treatment with CelluDress-PHMB (28.02.2014)

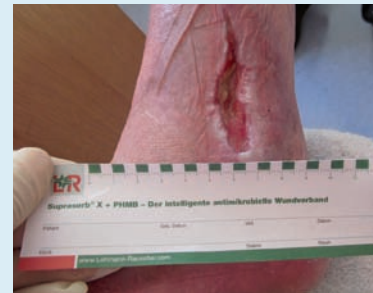

FIGURE 7. Continued improvement after a further 4 weeks (28.03.2014)

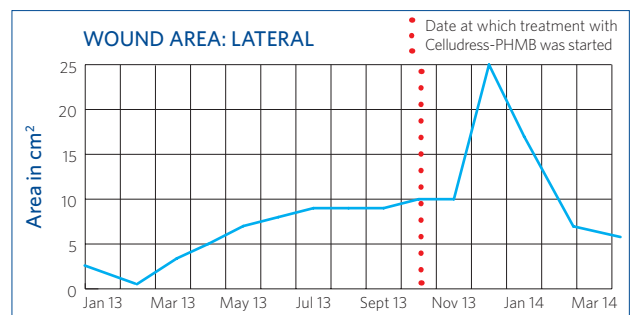
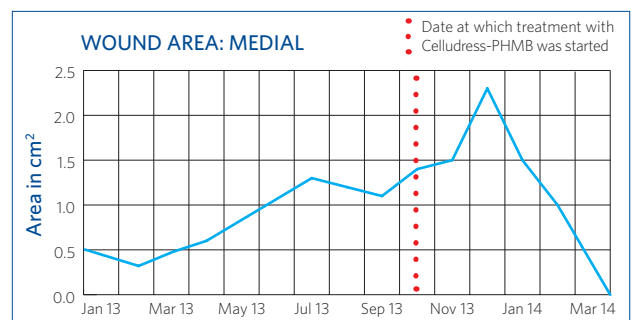
LATERAL ASPECT ULCER

The wound initially increased in size over the following four weeks (from 10.27cm² to 25.65cm²) due to debridement of devitalised tissue (Figure 5), but showed a dramatic reduction in size over the following three months of treatment (7.08 cm²) (Figure 6).

There was an initial increase in exudate, reducing over time and improving in colour. Over the course of treatment, the wound appeared less inflamed with reduction in localised swelling, erythema and local heat. The wound continued to improve with evidence of granulation in the wound bed (Figure 7).

SUMMARY

CelluDress-PHMB dressing was reported as safe and effective in these two postoperative venous ulcers, which had remained unhealed for three years due to the presence of metallic fixtures.



CASE STUDIES

CASE 3: MIXED ULCER DUE TO CIRCULATORY PROBLEMS

This 33-year-old woman presented in August 2013 with a five-year history of a mixed ulcer due to circulatory problems for which she had undergone several vascular surgical interventions. The wound was located on the right lateral aspect of the foot (Figure 1).

Following surgical consultation, amputation of the foot was recommended. However, the patient did not want to take this option due to the negative impact on her mobility and quality of life (she had young children).

A silver-containing Hydrofiber® dressing was applied, but due to wound-related pain (rated as 6 on a 0–10 scale), treatment was changed to CelluDress-PHMB. The wound was covered in a fibrinous coating and exudate level was moderate to high (Figure 2).

TREATMENT

The wound was cleansed with a PHMB wound irrigation solution (Prontosan W, B Braun) for 15 minutes. The wound was dried and a hydrogel applied to loosen the fibrinous coating. CelluDress-PHMB was cut to size and overlapped the edge of the wound by 1–2cm. This was covered by a secondary dressing with dressing changes scheduled for 3 times a week.

This treatment regimen was continued for 6 weeks during which time there was a reduction in wound area (from 17.89cm² to 14.79cm² — an overall reduction of 17.3% from baseline). There was good absorption of exudate, along with a reduction in wound-related pain (rated as 2 on a 0–10 scale) and reduction in the inflammatory markers (erythema and local heat) (Figure 3). The treatment was continued for a further 14 weeks, with the patient able to self-care under the guidance of the tissue viability nurse. There was further reduction in wound size (9.77cm² — an overall 45% reduction from start of treatment with CelluDress-PHMB) (Figure 4).

SUMMARY

Treatment with CelluDress-PHMB reduced the wound area, wound-related pain and inflammatory markers in this difficult-to-treat mixed ulcer. The patient is able to self-care and this has led to an improvement in her quality of life.

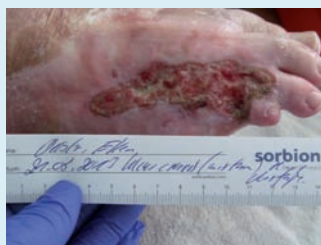

FIGURE 1. Ulcer on presentation (21.08.2013)

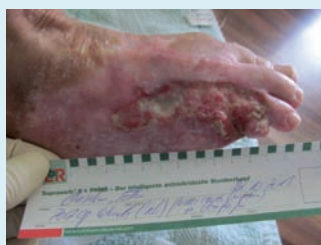

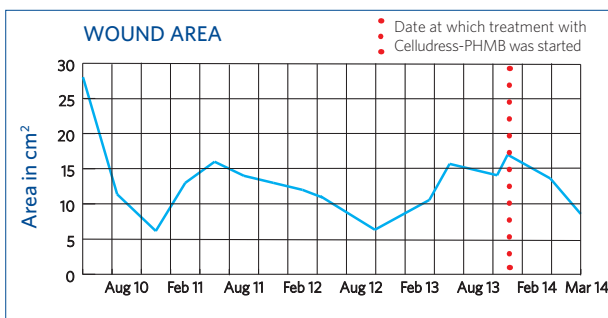
FIGURE 2. Ulcer at start of treatment with CelluDress-PHMB (22.10.2013)

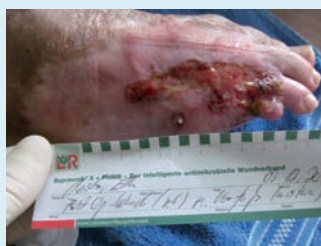

FIGURE 3. Improvement in ulcer seen after 6 weeks' treatment with CelluDress-PHMB (03.12.2013)

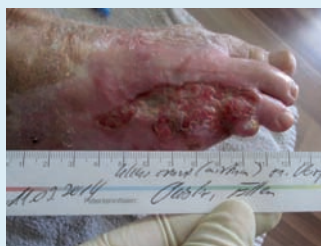

FIGURE 4. Continued signs of improvement (11.03.2014)



CASE 4: TRAUMATIC ULCER OF THE RIGHT LATERAL MIDFOOT

This 80-year-old gentleman with diabetes, who lived in a nursing home, presented in January 2014 with a traumatic ulcer of the right lateral midfoot of one month duration. The ulcer measured 1.59cm², had a fibrinous coating and showed signs of local infection with erythema and swelling. Exudate levels were moderate and the patient reported wound-related pain as 0-1 on a 0-10 scale due to neuropathy (Figure 1). It was decided to treat the wound using a cellulose PHMB dressing (CelluDress-PHMB) to manage the symptoms of local infection.

TREATMENT

The wound was cleansed with a PHMB wound irrigation solution (Prontosan W, B Braun) and a hydrogel applied. CelluDress-PHMB was cut to size and placed onto the wound. A hydropolymer absorbent dressing (Suprasorb P, Lohmann & Rauscher) was applied as a secondary dressing and appropriate pressure relief was given.

There was good absorption of exudate, which resulted in a rapid reduction in infection parameters and protection of the periwound skin. The wound reduced in size over 4 weeks of treatment (reducing from 1.59cm² to 0.61cm² — an overall reduction of 62% from the start of treatment with CelluDress-PHMB). Exudate levels reduced and there was good detachment of the fibrinous covering of the wound bed (Figure 2).

Over the following 4 weeks the wound continued to improve with a further reduction in wound size (0.15cm²) and evidence of granulation tissue in the wound bed and healthy epithelialisation (Figure 3). The wound was completely healed by 7 May 2014 and treatment was stopped.

SUMMARY

There was good reduction in inflammation over the first few days of using the dressing, with detachment of the rigid fibrinous eschar covering the wound bed. The wound progressed toward epithelialisation with no complications.

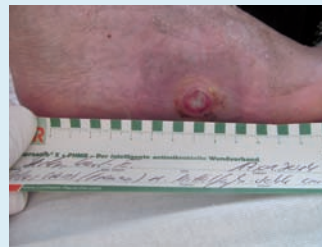

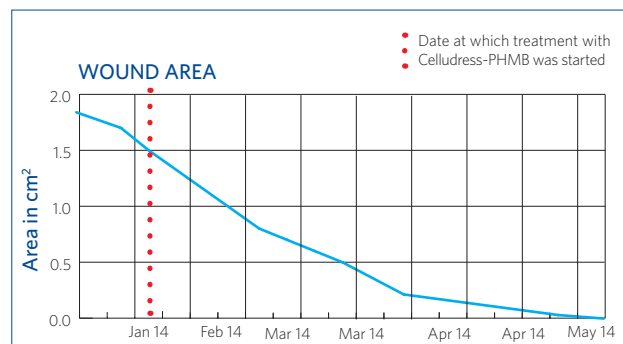
FIGURE 1. Ulcer at start of treatment with CelluDress-PHMB (17.01.2014)

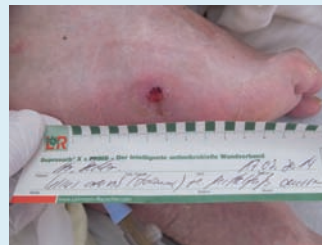

FIGURE 2. After 4 weeks' treatment with CelluDress-PHMB (17.02.2014)

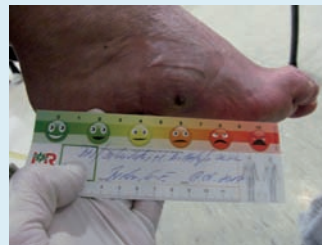

FIGURE 3. Ulcer showing healthy epithelialisation covered with eschar which is dissolving (07.05.2014)



CASE STUDIES

CASE 5: RECURRENT VENOUS LEG ULCERS

A 57-year-old gentleman with a 20-year history of recurrent venous leg ulcers and surgery for various veins, presented in June 2013 with ulcers to the medial and lateral aspects of the right ankle.

His ulcers had been treated using a wide range of wound care products, and more recently with silver-containing dressings (Aquacel® Ag, ConvaTec; Mepilex® Ag, Molnlycke; Urgotul® Silver, Urgo Medical). However, due to delayed healing and signs of local infection, the decision was made in November 2013 to change to a cellulose PHMB dressing (CelluDress-PHMB) (Figure 1).

At this time, the wound on the lateral aspect of the right ankle was covered with a fibrous coating, with low exudate. The patient reported wound-related pain as a 2 on a 0–10 scale.

TREATMENT

The wounds were cleaned with sodium chloride 0.9% and a hydrogel applied to support initial autolysis of the fibrinous coating. Celludress-PHMB was cut to size and placed onto the wound and covered with soft, non-woven absorbent secondary dressing. Inelastic compression was then applied to both legs. Dressings were scheduled to be changed 3 times per week.

Over the next 12 weeks, the exudate level initially increased to moderate due to autolysis. The patient's wound on the lateral aspect decreased in size (from 6.26cm² to 4.24cm²) and there was evidence of 50% granulation tissue coverage in the wound bed (Figure 2). Treatment was continued with further signs of improvement and reduction in wound size (1.63cm²) (Figure 3) — a 73% overall reduction in wound size from the start of treatment with Celludress-PHMB.

SUMMARY

CelluDress-PHMB was used to simplify treatment in this patient with persistent venous leg ulcers that were unresponsive to treatment using silver dressings. There was a rapid reduction in signs of inflammation, with reduction in wound area and formation of granulation tissue in the wound bed. A similar progression was seen in the ulcer on the medial aspect.

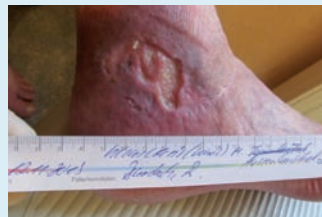

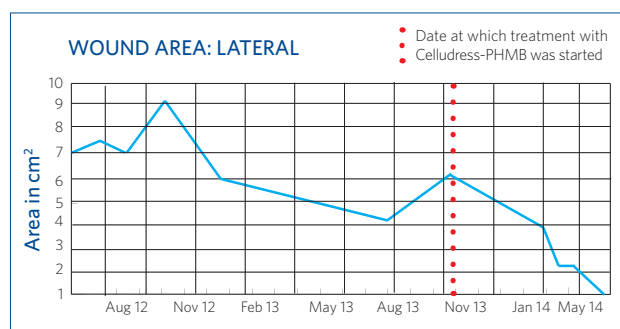
FIGURE 1. Lateral wound after treatment with silver dressings (12.11.2013). CelluDress-PHMB was started at the next dressing change, 3 days later

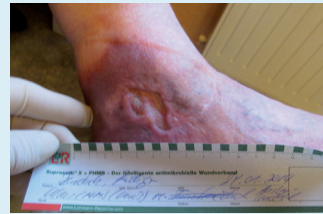

FIGURE 2. Wound after 6 weeks' treatment with CelluDress-PHMB (28.1.2014)

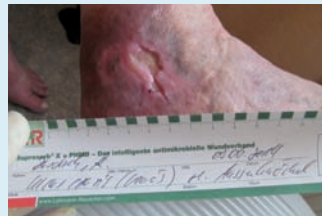

FIGURE 3. Continued improvement (03.06.2014)



CASE 6: CATEGORY III PRESSURE ULCER TO THE LEFT EAR

This 41-year-old gentleman had previously been involved in a motorcycle accident. He had been a coma for 24 months, and was conscious but unable to communicate. He was being cared for by his mother.

He remained in bed and had a preference for lying on his left side. A Category III pressure ulcer developed on his left ear, which presented as swollen, red and was painful (Figure 1). This was treated with a foam dressing, but the patient found this uncomfortable and made hearing difficult. It was decided to switch to a cellulose PHMB dressing (CelluDress-PHMB).

TREATMENT

The wound was cleansed with a PHMB wound irrigation solution (Prontosan W, B Braun). CelluDress-PHMB was cut to the size and shape of the ear. A hydrocolloid dressing (Suprasorb H Standard, Lohmann & Rauscher) was used as a secondary dressing. This was cut to shape and made a little larger to allow moulding and fixation to the ear. Dressing changes were performed 3 times weekly and appropriate pressure relief provided.

Over the next 8 days, the wound decreased in size (from 0.69cm² at baseline to 0.30cm²) and inflammation was reduced (Figure 2). Dressing changes were continued 3 times weekly and pressure relief maintained. The wound continued to improve and was fully healed on 7 July 2014 (Figure 3).

SUMMARY

CelluDress-PHMB was highly comfortable and easy to use in this difficult-to-dress wound. The wound improved in a relatively short period of time, helping to increase the quality of life in this patient.

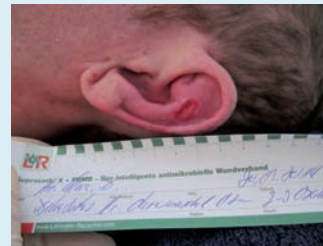

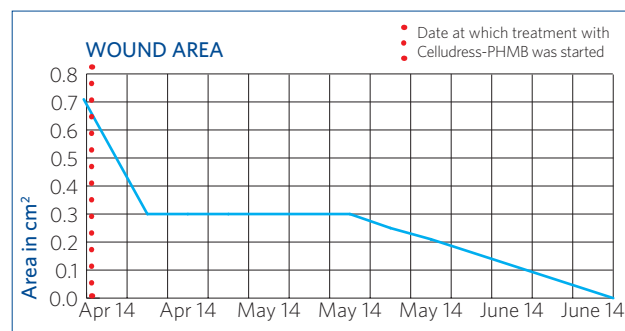
FIGURE 1. Ulcer on presentation (20.3.2014)

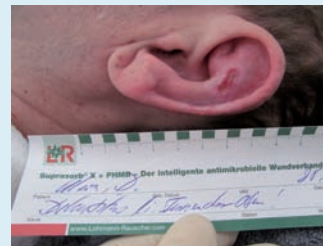

FIGURE 2. After 8 days' treatment with CelluDress-PHMB (28.03.2014)

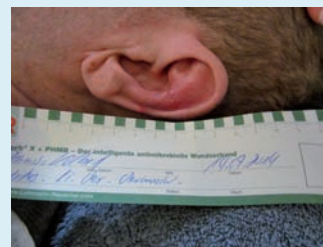

FIGURE 3. Wound healed (07.07.2014)



CASE 7: POSTOPERATIVE WOUNDS AFTER ERYSIPELAS WITH MRSA

A 50-year-old woman with secondary postoperative wounds developed erysipelas of the right calf/shinbone and right lateral ankle. Treatment with an antimicrobial foam dressing was initiated, but was not successful after 6 weeks of therapy with evidence of colonisation with MRSA on 17 December 2013 (Figure 1). It was decided to change her treatment to a cellulose PHMB dressing (CelluDress-PHMB).

TREATMENT

The wounds were cleaned with a PHMB wound irrigation solution (Prontosan W, B Braun). CelluDress-PHMB was cut to size and placed onto the wound, slightly exceeding the wound edges. A hydropolymer foam with adhesive border was applied as a secondary dressing. Dressing changes were scheduled to 3 times weekly, depending on exudate management. Offloading and repositioning was also implemented.

Over the next 4 weeks of therapy the wound on the right calf/shinbone decreased in size (from 5.88cm² to 5.02cm²) (Figure 2) with an excellent granulation response and good absorption of exudate. However, a wound swab did show some evidence of MRSA colonisation. The treatment regimen was continued unchanged with further improvement in the wound area seen after 2 months (1.07cm²) (Figure 3). A wound swab detected no evidence of MRSA in the wound on 17 March 2014. A similar outcome was seen in the wound on the right lateral ankle.

SUMMARY

MRSA colonisation was reduced to undetectable levels in both wounds with evidence of formation of granulation, epithelialisation and wound area reduction seen over the course of treatment with CelluDress-PHMB.

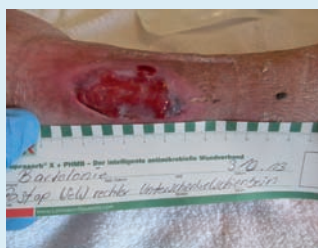

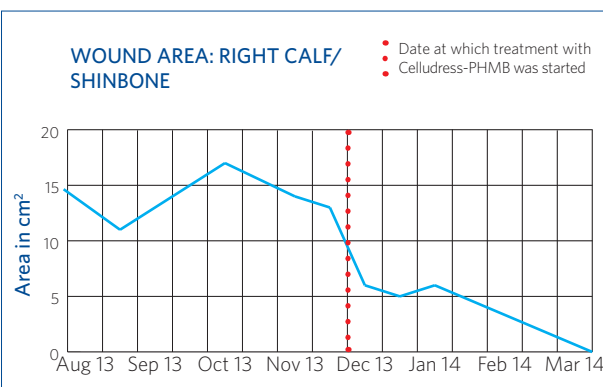
FIGURE 1. Wound on right calf/shinbone after 6 weeks' treatment with a silver dressing (17.12.2013)

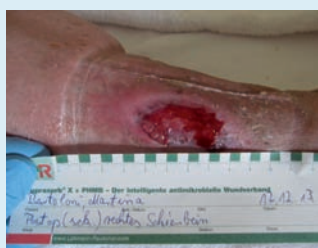

FIGURE 2. After 4 weeks' treatment with CelluDress-PHMB (16.01.2014)

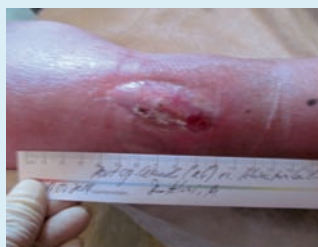

FIGURE 3. Further reduction in wound area with no evidence of MRSA (17.03.2014)



Published by

Wounds UK